

ENDOMETRIAL SARCOMA WITH RENAL METASTASIS: A CASE REPORT

Dr. S. K. Idris

Department of Radiology, Bayero University Teaching Hospital, Kano State.

SUMMARY

The case of a 30 year old lady that presented with 2 year history of vaginal bleeding and diagnosed as a case of endometrial sarcoma with right renal metastasis has been presented. The diagnosis made from ultrasound and computed tomography was histologically confirmed. The literature on the condition has been reviewed.

INTRODUCTION

Uterine sarcomas represent 2-5% of all uterine malignancies.¹ There are three types: Carcinosarcoma (also known as mixed mullerian tumor) is the most common (70%), leiomyosarcoma is next and endometrial stromal sarcoma (ESS) is the least common² and constitutes less than 10% of uterine sarcomas. Endometrial sarcomas are composed of cells that are identical to or closely resemble normal proliferative phase endometrial stromal cells. These tumors may arise from the endometrium but can also be seen in the setting of adenomyosis or endometriosis.³

Endometrial stromal sarcoma typically occurs in women between the ages of 42 and 59 years. Symptoms include abnormal uterine bleeding and pain. Risk factors are fairly non-specific and include prior pelvic radiation therapy, age, and race (slightly higher incidence among blacks).⁴ Other risk factors include nulliparity, late menopause, unopposed oestrogen therapy, polycystic ovaries and obesity.² The tumor is the 4th most prevalent female cancer in USA women with incidence of 34,000 new cases per year with 3,000 deaths.²

The tumor can invade the serosa, the adnexa and there could be peritoneal, pelvic, para aortic, bladder or bowel infiltration. Distant metastasis is to the lungs, brain and bone². The purpose of this report is to document the rare renal metastasis of endometrial sarcoma.

CASE REPORT

J. A. is a 30-year-old para 1+ 2, 1 alive that presented to the gynaecological emergency unit of UCH with a history of bleeding per vaginum for 2 years. The bleeding had been heavy within the past two months with several blood clots. There was history of lower abdominal pain and weakness and about two months ago, right loin pain. No history of fever, cough, vomiting or diarrhoea. Patient complained of being constipated most of the time.

Examination revealed a young lady, slightly pale, anicteric, afebrile and not in distress. Chest and cardiovascular system examination including the central nervous system were essentially normal. Abdominopelvic examination revealed an enlarged uterus of about 20 weeks size, tender and freely mobile. The adnexal organs were normal, the liver spleen and kidneys were not palpable. There was however right loin tenderness. A vaginal speculum examination revealed a normal but blood stained vulva and vagina. A provisional diagnosis of dysfunctional uterine bleeding was made.

Laboratory investigations were essentially normal except for a PCV of 28%. Chest x-ray was normal. Ultrasound revealed a bulky uterus containing an irregular centrally located echogenic mass which showed areas of calcifications (Fig 1). The right kidney was enlarged and show a distorted outline especially around its lower pole medially. The corticomedullary differentiation was preserved though there was early hydrocalycosis. The left kidney was within normal limits. The liver, spleen, pancreatic bed and para aortic lymph nodes were normal. A provisional diagnosis of a malignant endometrial tumor with a suspected right renal metastasis was made. An intravenous urogram showed prompt excretion by the left kidney, which was

normal in size and shape. It also showed normal pelvi-calyces and ureter. The right kidney was enlarged with a slightly delayed excretion and a bipolar length of 18cm. It showed marked hydrocalycosis and a dilated pelvis. The entire ureter was not visualized suggesting obstruction at the pelvi-ureteric junction probably from the large abdomino-pelvic mass or from enlarged lymph nodes.

The C.T. Scan examination showed a huge hypodense midline mass with surrounding rim of isodensity (Fig 2). It showed heterogeneous enhancement with intravenous contrast medium. The bladder and rectum were not infiltrated but were n-indented (Fig 3). The right kidney was enlarged with infiltrative ?metastatic foci. Some enlarged metastatic pelvic nodes were noted (Fig 4). A diagnosis of a malignant endometrial tumor with the right renal metastasis was made.

A total hysterectomy revealed a central utero-cervical mass partly necrotic and offensive. It measured 15 20cm in length. The bladder was attached to the mass but not infiltrated. The left kidney and ureter were normal. The right kidney was enlarged and baggy with a dilated ureter. Histology report a week post operatively confirmed an endometrial stromal sarcoma.

DISCUSSION

Uterine sarcomas comprise less than 1% of gynaecologic malignancies and 2% to 5% of all uterine malignancies.⁵ These tumors arise primarily from two distinct tissues.

1. Leiomyosarcoma from myometrial muscle and
2. Mesodermal (mullerian) and stromal sarcomas from endometrial epithelium.

The only documented etiologic factor in 10% to 25% of these malignancies is prior pelvic irradiation often administered for benign uterine bleeding 5 to 25 years earlier, this patient has no history of pelvic irradiation. The FIGO staging for carcinoma of the corpus uteri has been applied to uterine sarcoma.⁶ The disease is classified into four stages (I-IV) with stage IV being sub divided into

IVa and IV b. Our patient was classified as stage IVb because of distant metastasis (kidney and pelvic lymph nodes).

The role of radiology in the imaging of endometrial sarcoma cannot be overemphasized. Magnetic resonance imaging because of its excellent soft tissue contrast remains the imaging modality of choice.^{3,4} M R has 82 92% accuracy for staging and 74 87% accuracy for depth of invasion.² On M R, endometrial stromal sarcomas appear as large tumors in the endometrial cavity and/or myometrium. The signal is typically high on T1- weighted images and heterogeneously high on T2-weighted images. The tumor margins are typically irregular, often with marginal nodular lesions. Intramyometrial worm - like nodular extensions may be visible.^{3,4} Haemorrhage and necrosis are common as noted in this patient during surgery. Most endometrial stromal sarcomas show greater enhancement than normal myometrium. Overall, endometrial stromal sarcomas are difficult to differentiate from leiomyosarcomas and endometrial carcinomas.

Ultrasound is useful and it may show a normal sized/enlarged uterus, the endometrium is usually echogenic as in this patient with a thickness of >5mm. The endometrial echotexture is inhomogenous with irregular hypoechoic areas.^{2,4}

The prognosis for patients with uterine sarcoma is primarily dependant on the extent of the disease at the time of diagnosis.⁷ Surgery alone can be curative if the malignancy is contained within the uterus. The value of pelvic radiation is not established. Current studies consist primarily of phase II chemotherapy trails for advanced disease.⁸ Adjuvant chemotherapy following complete resection (stage I and II) has not been established to be effective in a randomized trials.⁹ Yet, other randomized trials have reported improved survival following adjuvant chemotherapy with or without radiation therapy.^{10,11,12}

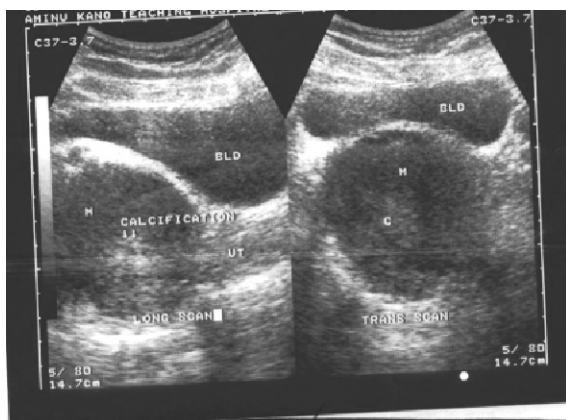


Fig 1: Ultrasound image showing bulky uterus containing an irregular centrally located echogenic mass with areas of calcification.

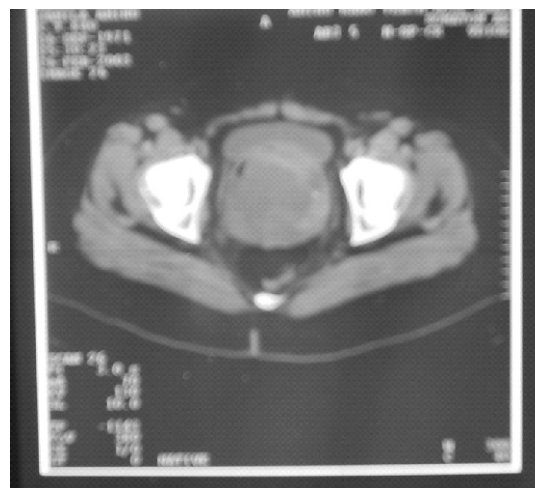

Fig 2: Axial C.T. Slice of the pelvis showing a huge hypodense mass (uterine) with a rim of isodensity.

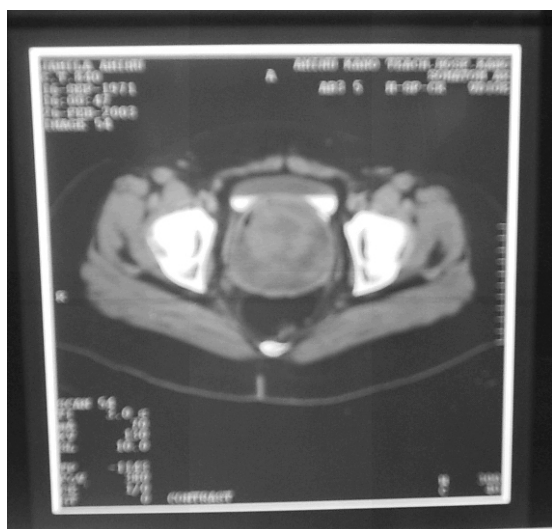

Fig 3: Contrast enhanced axial C.T. slice of the pelvis showing heterogeneous and marginal enhancement of the uterine tumour. The bladder was indented and displaced.

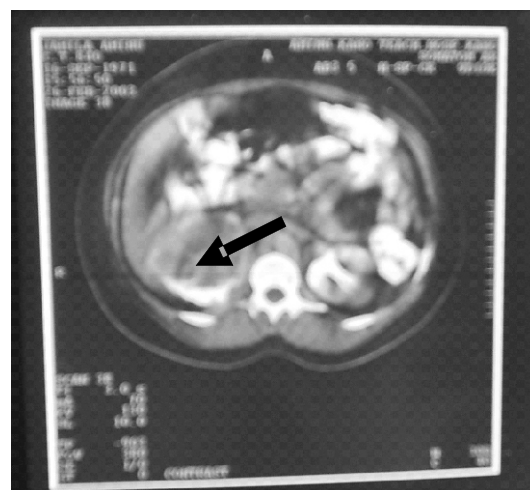

Fig 4: Axial slice of an abdominal C.T. scan showing an enlarged right kidney (arrow) showing peripheral contrast excretion. The left kidney was normal.

REFERENCES

1. Ueda M, Otsuka M, Hatakenaka M. MR Imaging Findings of Uterine Endometrial Stromal Sarcoma: Differentiation from Endometrial Carcinoma. *Eur Radiol.* 2001; 11: 28 33.
2. Wolfgang Dahnert M.D. *Radiology Review Manual.* 1996; 3rd Edition, Williams and Wilkins Co. Baltimore Maryland USA. pp 746.
3. Ueda M. , Otsuka M, Hatakenaka M. Uterine Endometrial Stromal Sarcoma Located in Uterine Myometrium: MRI Appearance. *Eur Radiol.* 2000; 10: 780 782
4. Gandolfo N, Gandolfo NG, Serafini G. Endometrial Stromal Sarcoma of the Uterus: MR and US Findings, *Eur Radiol.* 2000; 10: 776 779.
5. Forney JP, Buschbaum HJ: Classifying, Staging, and Treating Uterine Sarcomas. *Contemp Ob Gyn*, 1998; 18: 47 50, 55 56, 61 62, 64, 69.
6. Shepherd JH: Revised FIGO Staging for Gynaecological Cancer. *Br J Obstet, Gynaecol*, 1989; 96 : 889 892.
7. Major FJ, Blessing JA, Silverberg SG: Prognostic factors in early-stage uterine sarcoma. A Gynaecologic Oncology Group Study. *Cancer* 71, 1993: 1702 9.
8. Thigpen JT, Blessing HA, Beecham J: Phase II Trial of Cisplatin as First-Line Chemotherapy in Patients with advanced or recurrent Uterine Sarcomas: A Gynaecologic Oncology Group Study. *J Clin Oncol*, 1991; 9: 1962 6.
9. Omura GA, Blessing JA, Major FJ, Homesley H, Yordan E. A randomized clinical trail of adjuvant adriamycin in Uterine Sarcomas: A Gynaecologic Oncology Group Study. *J Clin Oncol* 1985; 3: 1240 5.
10. Piver MS, Lele SB, Marchetti DL. Effect of adjuvant Chemotherapy on Time to Recurrence and Survival of Stage I Uterine Sarcomas. *J Surg Oncol*, 1988; 38: 233 9.
11. Van Nagell JR, Jr, Hanson MB, Donaldson ES. Adjuvant Vincristine, D a c t i n o m y c i n , and Cyclophosphamide Therapy in Stage I Uterine Sarcomas. A Pilot Study. *Cancer* 57, 1986; 57: 1451 4.
12. Peters WA, Rirkin SE, Smith MR. Cisplatin and Adriamycin Combination Chemotherapy for Uterine Stromal Sarcomas and Mixed Mesodermal Tumors. *Gynaecol Oncol*, 1989; 34: 323 7.