

Chest Radiographic Patterns in HIV Associated Kaposi's Sarcoma in Benin City, Nigeria

*Ademola A. Adeyekun,¹ Abel N. Onunu,¹ Bob A. Ukou,² Stanley O. Okugbo

Departments: *Radiology, ¹Medicine and ²Surgery, University of Benin Teaching Hospital, PMB 1111 Benin City, Nigeria. Correspondence: *Ademola A. Adeyekun, Email: adeyekunaa@yahoo.com

ABSTRACT

Background

Kaposi's sarcoma (KS) is the most common tumour among patients with HIV infection. Pulmonary involvement occurs commonly in critically immunosuppressed patients, especially with muco-cutaneous involvement. Diagnosis of pulmonary involvement can be made by a combination of clinical, radiographic and laboratory findings. There is paucity of data on the imaging appearances of this condition in the Nigerian populace.

Patients and Methods

This was a retrospective study. Thirty-three patients who attended the HIV/AIDS clinic or were admitted into the medical wards, with KS were included in the study. Clinical data (from case records) and radiographic images were accessed. There were 18 males (54.5%) and 15 females (45.5%); M: F; 1.2:1. Among other laboratory tests, the CD₄₊ cell count was for each patient was recorded. Each subject's posteroanterior chest radiograph taken in full inspiration was retrieved. The retrieved radiographs were reviewed and classified as normal or abnormal. Abnormal findings were further classified into pulmonary or cardiac lesions. Correlation of radiographic findings with the CD₄₊ cell count was done.

Results

Mean age of subjects was 37.53±9.86years. The mean CD₄ cell count was 165.97±100.49 cells/cu mm. Thirty-three patients had cutaneous lesions, while 7 patients and 3 patients had oral and ocular lesions respectively. Three patients had lymphoedema. Eighteen patients (54.5%) had normal chest radiographs, while 15(45.5%) had abnormal findings. Abnormal findings were lobar consolidation; 6 patients (40%),

symmetrical alveolar densities, with adenopathy ("pneumocystis carinii patterns"); 6 patients (40%), cardiomegaly with alveolar infiltrates; 3 patients (14%). When all the subjects were considered, the CD₄₊ cell count did not correlate significantly with chest radiographic abnormality.

Conclusion

This study found a high level of chest involvement in Kaposi's sarcoma, thus confirming previous reports on the subject. The CD₄₊ counts were lower in those with abnormal chest radiographic findings, suggesting more immunodeficiency. The difference was, however, not statistically significant.

INTRODUCTION

Kaposi's sarcoma (KS), was first described by Moritz von Kaposi in 1872 as a low-grade mesenchymal tumor involving blood vessels. It is the most common tumour among patients with HIV infection, and pulmonary infection occurs commonly in critically immuno suppressed patients who commonly have had a preceding muco-cutaneous or digestive involvement. (1) Pulmonary involvement in HIV-infected patients diagnosed with KS is associated with a low CD4 cell count, suggesting that pulmonary KS may be related to late presentation of HIV disease. (2)

The diagnosis of pulmonary involvement in Kaposi's sarcoma usually can be made by a combination of clinical, radiographic and laboratory findings, together with the results of bronchography and transbronchial biopsy. (4, 5) High resolution computed tomography scan of the chest can reveal peribronchovascular and interlobular septal thickening, bilateral and symmetrical ill-defined nodules in a peribronchovascular distribution, fissural nodularity, mediastinal adenopathy, and pleural

effusions. (6, 7).

There is paucity of information on KS in HIV-infected patients in Nigeria with figures of 0.52% incidence quoted, though the prevalence of KS in Africa generally has been on the increase as a result of the human immunodeficiency virus (HIV) pandemic (10,11,12). Specifically, data on chest involvement in KS remain sparse.

Therefore this study aimed at determining, by chest radiography, the degree of thoracic involvement in KS, the patterns of chest involvement. It also aimed at contributing to the data on Kaposi's sarcoma among Nigerians.

PATIENTS AND METHODS

All patients diagnosed with HIV infection presenting with Kaposi's sarcoma and admitted into the medical wards of the University of Benin Teaching Hospital (UBTH), were included in this study. This was retrospectively done over a one year period (between April 2004 and March 2005). Thirty-three such patients were studied. All the patients also had symptoms referable to the respiratory system, such as cough, dyspnoea, tiredness, chest pain, among others. Using the case records, details of patient biodata, clinical symptoms and signs, as well as past medical history were recorded, on a pro-forma. The chest radiographs of the patients were also retrieved. Approval of the ethical committee was sought and obtained.

Serological test for HIV was done using the ELISA method, while confirmatory test was by rapid ELIZA test kits. The CD4 cell count was done using the Dyna Bead method. All patients with clinical evidence of KS had histopathology examination of biopsy specimen for confirmation of diagnosis. Each subject had chest radiographic examination in full inspiration, using the following factors; kVp (peak kilovoltage) =65; mAs (milliamperagesec) =12-15, and ffd (focus-film distance) =150cm.

The retrieved radiographs were then reviewed and reported by the first author (Consultant Radiologist), and first classified into normal and abnormal. Abnormal findings were further classified into cardiac and pulmonary lesions.

The radiographic findings were then correlated with the CD₄ cell counts.

Data analysis involved the use of SPSS Ver.13. Mean values, percentages and frequency tables were used to express results. Chi-square tests (Pearson's) and ANOVA were used to correlate variables where appropriate. Statistical significance was determined at p-values less than 0.05.

RESULTS

A total of 33 HIV infected patients diagnosed with KS, consisting of 15males (45.5%) and 18 females (54.5%) were studied. The mean age of subjects was 37.5±9.87 years.

CD4+ cell count:

The mean CD4 cell count for all subjects was 174.26±98.41 cells/cu mm. Females had a lower CD4+ cell count (162.15±83.77 cells/comm.), compared to males (179.92±112.46 cells/cu mm). However, this was not statistically significant (p=0.515). Fig. 1

Muco-cutaneous lesions:

Seven patients (28%) had oral lesions, while 3 patients (9.1%) had ocular lesions. Three patients had lymphoedema. All 33 patients had cutaneous lesions consisting of macular rashes (21patients or 63.6%), plaques (22patients or 66.7%), papules (13 patients or 39.4%), and nodular lesions; 15 patients or 45.5%).

Chest radiographic findings:

Fifteen patients (45.4%) had normal chest radiographs while 18 patients (54.5%) had abnormal radiographs. Eleven females (61.1%) had radiographic abnormalities compared with 7 males (38.9%); this was not statistically significant (p=0.227).

Bilateral, symmetrical, alveolar densities with hilar/ mediastinal adenopathy, was seen in 7 patients (38.9%); lobar consolidation was noted in 8 patients (44.4%). These lesions predominantly involved the mid-lung zones. Cardiomegaly with hilar vascular congestion (cardiac failure) was seen in 3 patients (16.7%). Subjects with abnormal chest findings had a lower CD4 cell count

compared with those with normal chest radiographs (139.53 ± 32.24 cells/cu mm Vs 209.00 ± 121.12 cells/cu mm). This was not statistically significant ($p=0.414$)- Figure 3.

Figure 1. Bilateral mid and lower zone inhomogeneous densities, more marked on the right. The lesions resolved on Trimethoprin/Sulfamethoxazole combination therapy.

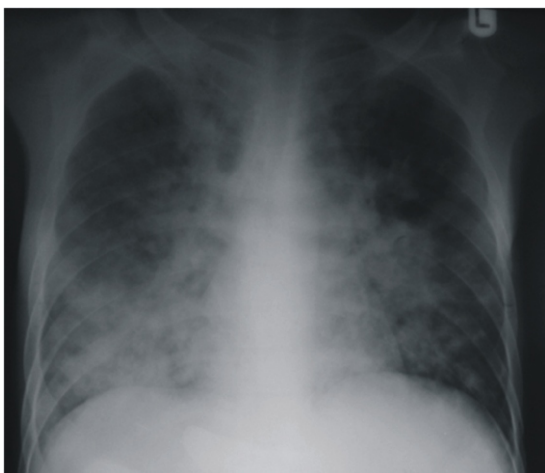


Figure 2. Left sided pleural effusion in a patient with KS.

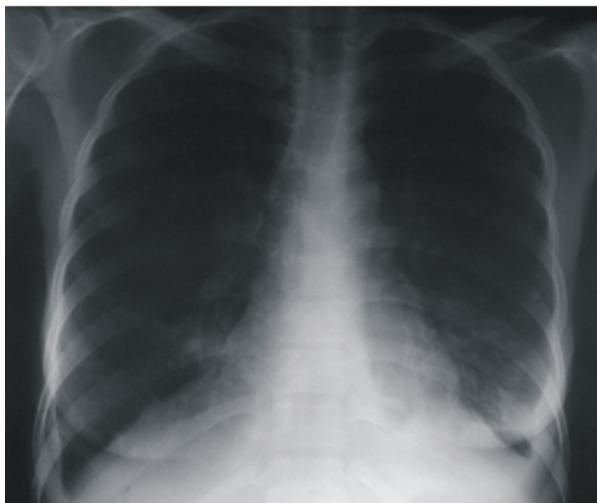

Figure 5 Bilaterally symmetrical alveolar densities, possible with adenopathy, in a patient with suspected to have pneumocystis carinii pneumonia. →

Figure 3. Lobar Consolidation in a case of Kaposi's sarcoma.

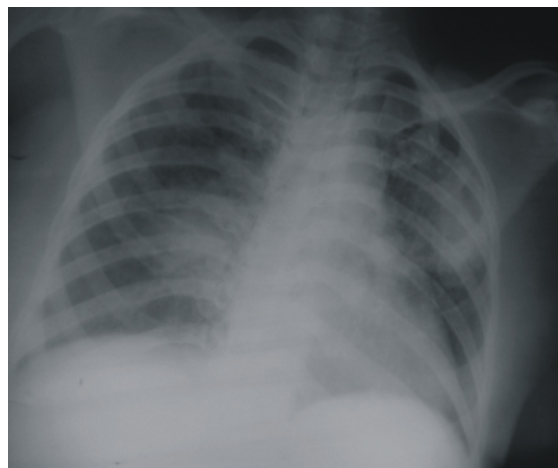

Figure 4 Inhomogeneous opacities, with cystic components, in both lung fields suspected to be due to PCP. There was response to antimicrobial therapy.

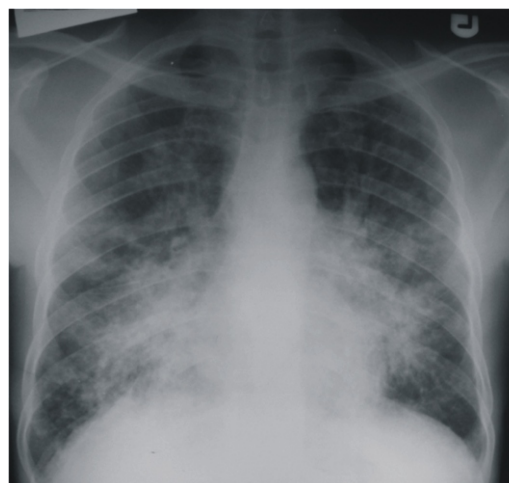
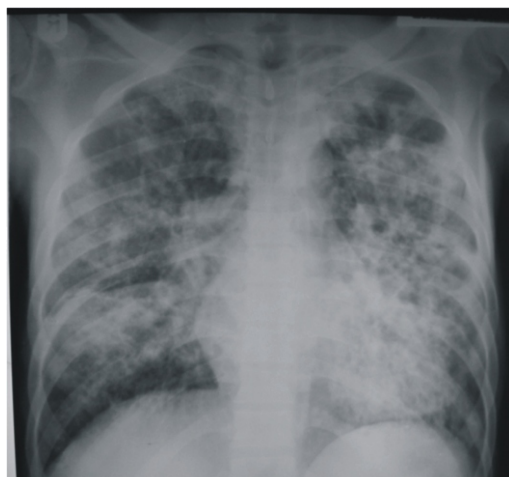
Figure 6. Cardiac failure in patient with HIV coexisting with Kaposi's sarcoma.

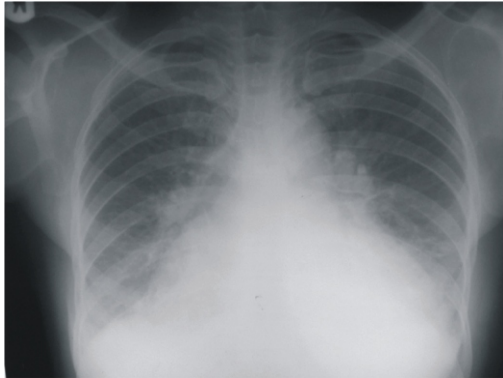


Table 2: Frequency Distribution Table for Muco-cutaneous lesions.

Type/location of lesions	Frequency n (%)
Oral	7 (28)
Ocular	3 (9.1)
Cutaneous:	
*macular	21 (63.3)
*plaques	2 (6.7)
*nodular	15 (45.5)
*papular	13 (39.4)
Lymphoedema	3 (9.1)

Table 1: Mean CD4 cell count for all subjects

Gender	Frequency (n)%	Mean CD ₄ count (cells/cu mm)
Females	18 (54.5)	162.16±83.77
Males	15 (45.5)	186.37±114.58
Total	33 (100)	174.26±98.67

$X^2 = 0.434$; $p = 0.515$ ns* (not statistically significant).

Table 3: Patterns of chest radiographic findings.

Finding	Frequency n (%)
Normal	15 (45.4)
Abnormal	(54.6)
*symmetrical alveolar densities with adenopathy	7 (24.2)
*lobar consolidation	8 (24.2)
*cardiomegaly with alveolar infiltrates	3 (9.1)
Total	33 (100)

Table 4: Correlation of CD4 cell count with chest radiographic findings.

Gender	Chest x ray findings	N	Mean CD4 cell count
Female	Normal	7	201.00±73.81
	Abnormal	11	123.31±93.74
	Total	18	162.15±83.41
Male	Normal	8	217.00±169.32
	Abnormal	7	156.75±60.84
	Total	15	186.92±114.46
	Normal	15	209.00±121.12
	Abnormal	18	139.53±76.79
	Total	33	174.26±±98.40

$X^2 = 0.989$; $p = 0.414$ (ns)

Chest x-ray Finding	Female n (%) / Mean CD4 ⁺ count	Male n (%) / Mean CD4 ⁺ count	Total n (%) / Mean CD4 ⁺ count
Normal	7 () / 201.00±73.81	8 () / 217.00±169.32	15 (45.4) / 209.00±121.12
Abnormal	11(61.1%) / 123.31±93.74	7 () / 156.75±60.84	18 (54.6) / 139.53±32.24
Total	18 (54.5) / 161.15±88.7	15 (45.5) / 179.92±112.46	33(100.0) / 174.26±76.6

$X^2 = 0.989$; $p = 0.414$ (not statistically significant)

DISCUSSION

Previous reports have noted that patients with lung KS have previous cutaneous lesions or visceral involvement (2). All our 33 subjects in this study had cutaneous lesions, which combined with histological confirmation, formed the basis for diagnosis of Kaposi's sarcoma in these patients. The lesions included plaques, macules, nodular and papular lesions. Thirteen patients (or 39.4%) had oral and ocular lesions, with diarrhea, which may be indicative of visceral involvement. Lymphoedema of the legs was noted in 3 patients, which is another feature of late presentation of KS.

The mean CD4 cell count of patients studied was lower than 200 cells/cu mm, with females having lower values than males. This observation of low CD4 cell count agrees with that of Palmieri et al, (3) in their study on HIV-infected patients with and without pulmonary KS, in which they found that pulmonary involvement was associated with a low CD4 count and late presentation of HIV infection. However, in this study we found no statistically significant relationship between the radiographic abnormalities noted and level of immunosuppression. This may be related to varying degrees of antiretroviral therapy in these patients at the time of presentation. Although the patients were not started on antiretroviral drugs immediately on admission at UBTH, it was possible that some had started treatment at some of the referring private or secondary centres.

The diagnosis of pulmonary KS can be made by a combination of clinical, radiographic and bronchoscopic methods, as well as transbronchial biopsy. (5). The present study employed only a combination of clinical and radiographic methods due to reasons of cost and non-availability of equipment for the other methods of diagnosis, such as bronchoscopy. The pattern of abnormalities noted ranged from bilateral perihilar densities with mid and lower zone preponderance, some associated with hilar adenopathy-the pneumocystis carinii pneumonia (PCP) pattern. This is similar to the observation made by Retrespo and colleagues when they studied imaging manifestations of pulmonary KS. (6). However, our diagnosis of pneumocystis carinii pneumonia was basically

presumptive and was actually supported by the improvement in clinical and radiographic picture after institution of therapeutic trial of trimethoprim and sulfamethoxazole combination for the patients. It is pertinent to note that high resolution CT scan (HRCT) can define these lesions better, with more specificity and sensitivity than chest x-rays, and can also provide data leading to the suspicion of diagnosis of pulmonary KS.(13). HRCT was not used for our study subjects due to reason of cost and availability. The most frequent CT findings include interstitial thickening, initially perihilar, and then progressing to the periphery. The involvement is predominant in the middle and lower third of the lungs, preserving the upper lobes. This study though limited to chest radiography also found mid and lower zone preponderance of lesions.

Cardiac disease associated with HIV/AIDS is said to be common and can manifest in a variety of lesions. (14). It may also be the first sign of the disease. (15) Manifestation may range from dilated cardiomyopathy, pericardial disease and left ventricular dysfunction. (16). There have been reports from part of Africa (including Nigeria) describing cardiovascular involvement in HIV/AIDS. (17, 18) Three of our study subject with abnormal chest radiographs had features of cardiac enlargement and pulmonary oedema (cardiac failure). Anaemia was present in these patients and was possibly the aetiologic culprit, though other conditions like myocarditis, pericardial lesions and dilated cardiomyopathy could not be excluded. Unfortunately the echocardiographic and electrocardiographic records of these 3 patients could not be found. We think it worthwhile therefore to highlight the possible cardiac complications that may be seen in patients with Kaposi's sarcoma.

CONCLUSION

Kaposi's sarcoma can involve/affect the chest to very significant extent. Both the pulmonary and cardiac systems can be involved. The lack of significant association between thoracic involvement and level of immunosuppression may be attributable to the varying levels of antiretroviral therapy in our study subjects

REFERENCES

1. Mbulaiteye SM, Parkin DM, Rabkin CS. Epidemiology of AIDS related malignancies: an international perspective *Hematol Oncol Clin North Am* 2003; 17: 673-96
2. Pantanowitz L, Mullen J, Dezube BJ. Primary Kaposi's sarcoma of the subcutaneous tissue. *World J Surg Oncol* 2008; 6:94
3. Palmieri C, Dhillon T, Thirlwell C, Newson-Davis T, Young AM, Nelson M et al. Pulmonary Kaposi's sarcoma in the era of highly active antiretroviral therapy. *HIV med* 2006; 7: 291-3.
4. Kang EY, Staples CA, Mc Guinness G, Primack SL, Muller LN. Detection and differential diagnosis of pulmonary infections and tumours in patients with AIDS; value of chest radiography versus CT. *AJR Am J Roentgenol* 1996; 166: 15-19.
5. Retrespo CS, Martinez S, Lemos JA, Carillo JA, Lemos DF, Ojeda P et al. Imaging manifestations of Kaposi's sarcoma. *Radiographics* 2006; 26: 1169-85.
6. Godoy MC, Rouse H, Brown JA, Philips P, Forrest DM, Muller LN. Imaging features of pulmonary Kaposi's sarcoma associated immune reconstitution syndrome. *AJR Am J Roentgenol* 2007; 189:956-65.
7. Akinsete I, Akanmu A S, Okany CC. Spectrum of clinical disease in HIV-infected adults at the Lagos University Teaching Hospital: a five year experience (1992-96). *Afr. J Med med Sci.* 1998; 28:147-51.
8. Onunu A N, Okoduwa C, Eze E U, Adeyekun A A, Kubeyinje E P, Schwarz R A. Kaposi's sarcoma in Nigeria. *Int J Dermatol* 2007; 46: 264-7.
9. Nnoruka EN. Epidemic (human immunodeficiency virus-related) Kaposi's sarcoma in West Africa women. *Int J Dermatol* 2003; 42: 794-99.
10. Joint United Nations Programme on HIV/AIDS. Epidemiological fact sheets on HIV/AIDS and sexually transmitted infection in Nigeria, 2002 update (revised). Geneva, Switzerland: UNAIDS/WHO, 2002.
11. Chakib A, Hilwa W, Marih L, et al. Kaposi's sarcoma in Morocco (apropos of 50 cases). *Bull Soc Pathol Exot* 2003; 96: 86-89.
12. Gasparetto TD, Marchiori E, Lourenco S, Zanetti G, Vianna AD, Santos AA, Nobre LF. Pulmonary involvement in Kaposi's sarcoma; correlation between imaging and pathology. *Orphanet Journal of Rare Diseases* 2009; 4:18.
13. Marchiori E, Muller LN, Soares Souza A Jr, Escuissato DL, Gasparetto EL, Franquent T. pulmonary disease in patients with AIDS: high resolution CT and pathologic findings. *AJR Am J Roentgenol* 2005; 184: 757-64.
14. Kaul J, Fishbein MC, Siegel RJ. Cardiac manifestation of acquired immunodeficiency syndrome: a 1991 update. *Am Heart J* 1991; 122: 535-44.
15. Courier PF, Jacob AJ, Foreman AR et al. Heart muscle disease related to HIV infection: prognostic implications. *BMJ* 1994; 309:1605-7.
16. Proenca L. AIDS and the heart. *Rev Port Cartol* 1993; 12:455-9.
17. Noreuil TO, /Dinh HA. Dilated Cardiomyopathy as an early and rapidly progressive presentation in a woman with acquired immunodeficiency syndrome. *South Afri Med J* 1993; 86: 405-8
18. Danbauchi SS, Okpapi J U. Cardiovascular involvement in HIV/AIDS: Report of 3 cases. *WAJM* 2001; 20: 261-4